


МІНІСТЕРСТВО ОСВІТИ І НАУКИ УКРАЇНИ
ХАРКІВСЬКИЙ НАЦІОНАЛЬНИЙ УНІВЕРСИТЕТ
РАДІОЕЛЕКТРОНІКИ

МАТЕРІАЛИ
XX ЮВІЛЕЙНОГО МІЖНАРОДНОГО
МОЛОДІЖНОГО ФОРУМУ

РАДІОЕЛЕКТРОНІКА ТА МОЛОДЬ У ХХІ СТОЛІТТІ

Том 1



Харків 2016

DEVELOPMENT OF METHOD OF CT IMAGE PROCESSING FOR THE DIAGNOSIS OF CHRONIC SINUSITIS

Ibrahim Younouss Abdelhamid

Scientific Supervisor – Dr. Techn. Sc. Prof. Avrunin O.G.¹,
As. Prof. Shushliapina N.O.²

¹ Kharkiv National University of Radio Electronics,
(61166, Kharkiv, 14 Nauka Ave., Dept. BME, Tel. (057) 702-13-64)

² Kharkiv National Medical University,
(61022, Kharkiv, 4 Nauka Ave., Dept. ENT, Tel. (057) 705-67-13)
E-Mail: Me9edo@gmail.com

The problem of nasal pathologies is currently one of the most urgent disease needed treatment in the world. The surgery planning for these pathologies without the use of computed tomography (CT) and modern computer technology is very difficult. Lack of informative diagnostic methods does not allow adequate therapy, as well as to implement and use in developed countries accepted standards of treatment. This urgent task is to find out the most important and informative diagnostic features allowing to identify specific pathology with the maximum degree of probability [1-3].

]One of the known quantitative diagnostic methods which are used during work with medical images (X-ray, X-ray CT, MRI) is analysis of densitographic data representing the profile of distribution of intensity (brightness) along a defined path [4, 5]. Normally densitogram of paired organs is characterized by spatial symmetry with small deviations related to individual anatomical variability. For certain pathologies (inflammatory, neoplastic, injuries) is a violation of the spatial symmetry, so it is possible to determine the nature and severity of the disease by analysis of degree of these violations.

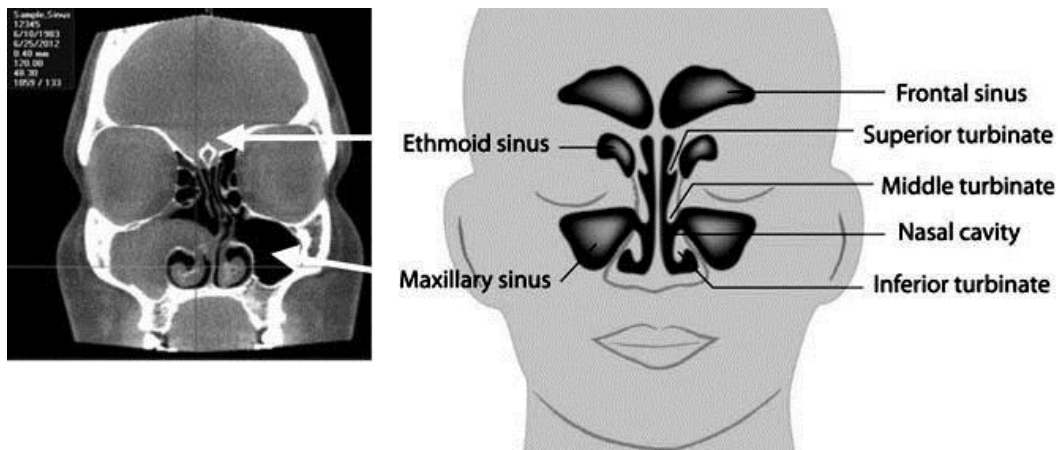


Fig. 1- CT scan of sinuses and their anatomic compliance

Currently, there is a trend towards greater automation of the basic routine operations performed by a specialist. The computer at the same time allows the expert report only extended, additional diagnostic information and is not involved in the complex process of formation of the diagnosis. Therefore, the aim of this work is the development of methods, algorithms and software for the diagnosis of chronic sinusitis by use of CT.

I developed algorithms for pre-processing of CT image for the diagnosis of chronic sinusitis. The greatest attention is paid to the development of the algorithm for post-processing of CT-densitogram (fig.2).

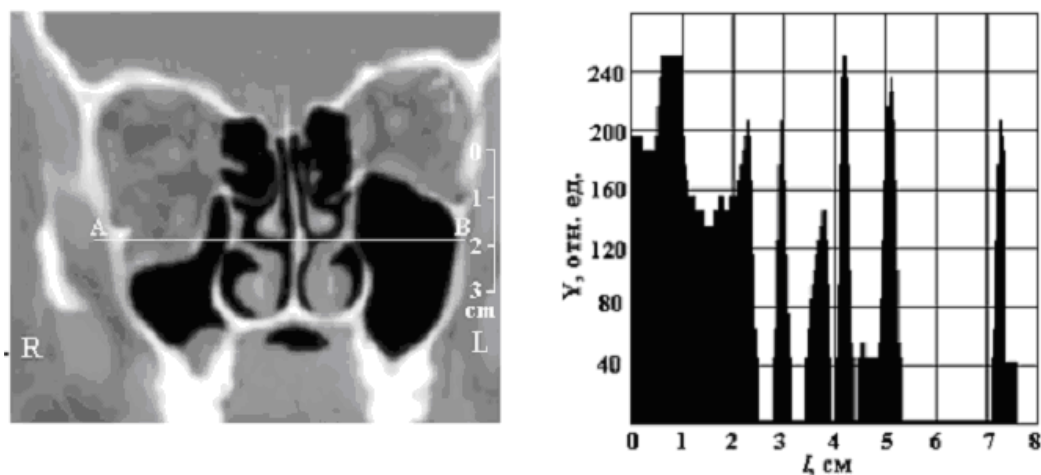


Fig. 2 - Choice of the path AB on CT and densitogram along AB

The analysis of properties of CT images showed the necessity of use averaging filtering algorithms that allow eliminate pulse noise with little blurring contours of objects. Prior to the densitometric analysis is necessary to draw average densitogram and eliminate minor local extrema.

To determine the geometrical characteristics of the damaged areas and structures of paired organs by use of densitogram I propose an algorithm based on the analysis of symmetric parts of densitogram.

The presence of chronic sinusitis can be detected by calculation of the thickness of the mucosa of the maxillary sinus. If the thickness of the mucosa significantly exceed 5 mm in a few weeks, it is possible to verify the presence of a chronic process, especially when full occlusion is in the sinuses fistulae.

The result of the development of special graphical software allows perform pre-processing of tomographic data, drawing and automated analysis of CT-densitogram which increases the diagnostic value of the method of densitometry, particularly in determining the signs of chronic sinusitis.

Reference:

1. The role of paranasal sinuses in the aerodynamics of the nasal cavities /H. Farouk, E. Abaida, A. Khaleel, O. Avrunin //International Journal of Life Science and Medical Research.–2012.–Vol. 2. №3.– P.52-55.
2. H.F. Ismail Saied, A.K. Al_Omari, O.G. Avrunin. An Attempt of the Determination of Aerodynamic Characteristics of Nasal Airways// Image Processing & Communications, challenges3, AISC 102. pp 303-310 Springer-Verlag Berlin Heidelberg.- 2011: P. 311-322.
3. A.K. Al_Omari, H.F. Ismail Saied, O.G. Avrunin, Analysis of Changes of the Hydraulic Diameter and Determination of the Air Flow Modes in the Nasal Cavity // Image Processing & Communications, challenges3, AISC 102. Springer - Verlag Berlin Heidelberg.-2011: P. 303-310.
4. Construction of personalized anatomic model of diaphragm of man / V.G. Dudenko, O.G. Avrunin, M.I. Tymkovich, V.V. Kurinnoy // Ж. експеримент. і клін. мед. – 2014. – № 2(63). – С. 68-70
5. O. G. Avrunin, M. Alkhorayef, H. F. I. Saied, and M. Y. Tymkovich, The Surgical Navigation System with Optical Position Determination Technology and Sources of Errors, Journal of Medical Imaging and Health Informatics, 5, 689- 696 (2015).